

SAMPLE

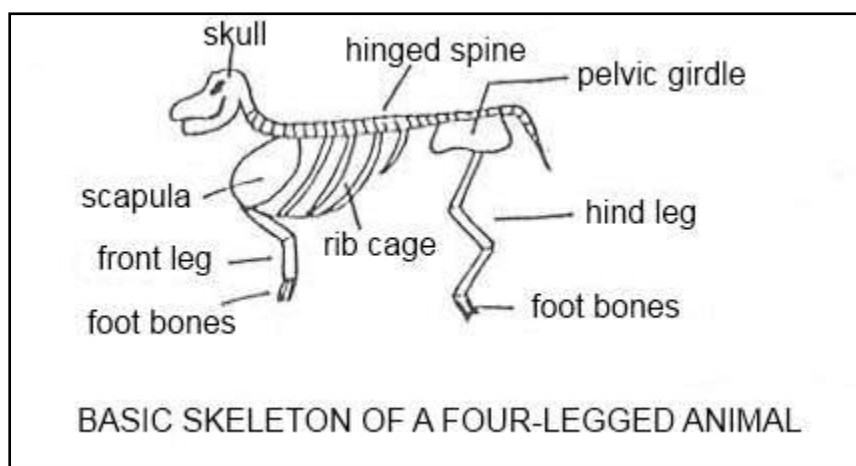
The Skeleton

Lesson Aim

Explain the skeletal system of a typical mammal, in terms of both structure and function.

BONE

Bones are living structures. They have blood vessels, lymphatic vessels, and nerves. They grow, repair themselves and are subject to diseases. Bones are connected in a system of moveable and immoveable joints to form the skeleton. The skeleton serves as a frame to which voluntary striated muscles are attached. The skeleton and the attached muscles make up what is known as the carcass, after the animal's death. A butcher may then cut up the carcass to form the meat cuts.



HOW BONES ARE FORMED

Bones begin life as cartilage. As the young animal develops in the mother's womb, the skeletal system becomes organised into a framework of cartilage. Before birth, there is a certain amount of hardening of the limb bones to allow the animal to stand shortly after delivery. However, the greater part of the skeleton is cartilage at birth. After birth, hardening of all parts of the skeleton begins. This process continues throughout life until, in old age, very little cartilage is left and the bones are old and brittle. The process of hardening cartilage into bone is called ossification.

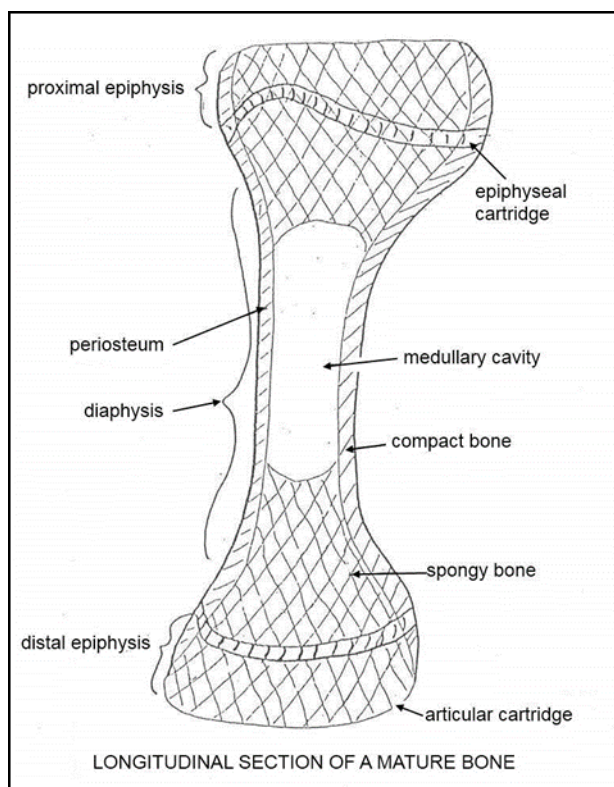
Ossification is achieved by bone-forming cells called *osteoblasts* (osteo- means "bone" in Greek). The old osteoblasts produce bone tissue (called osteoid tissue) and also secrete the enzyme phosphatase which allows calcium salts to be deposited in the newly formed bone tissue. This makes the tissue hard or bone-like.

The osteoblasts are connected by a system of tiny canals called canaliculi which bring tissue fluid to each osteoblast. The canals and special cells make a network which forms the frame of the bone. The newly made bone tissue is laid down on this mould and, in time, becomes calcified or hardened. Once the bone tissue is hardened and mature, the osteoblast change into osteocytes (mature bone cells). They sit in small cavities (called lacunae) within the calcified (hardened) bone tissue. The system of canals still connects the lacunae and now serves to carry tissue fluid that is essential for the maintenance of life of the osteocytes.

THE ANATOMY OF BONE

There are several different types of bone which will be discussed later in this section. A typical bone is made up of a shaft and two ends (known as extremities). The outer shell of a typical bone is known as compact bone.

This layer is hard and covers most of the surface of the bone. The two extremities consist of spongy bone. This is made up of plates that form a porous network.



The spaces within this network are usually filled with bone marrow which is a soft, fatty substance. Inside the shaft is the medullary cavity which is a hollow that is filled with bone marrow. The marrow is red in young animals but gradually turns yellow.

Some bone ends are involved in joint movement. Where this occurs the extremity is covered with a thin layer of smooth cartilage. This cartilage is called the articular cartilage and its job is to provide a friction-free surface to aid movement.

Around the entire surface of the bone (except where there is articular cartilage), is a thin, fibrous membrane called the periosteum. It is a specialized connective tissue covering all bones of the body, and possessing bone-forming potentialities.

In adult animals, it consists of two layers that are not sharply defined. The external layer being a network of dense connective tissue containing blood vessels, and the deep layer composed of more loosely arranged collagenous bundles with spindle-shaped connective tissue cells and a network of thin elastic fibres. Bone-forming cells are located here and are responsible for laying down bone to increase the width of long bones. It also lays down bone in response to healing at places where fractures have occurred.

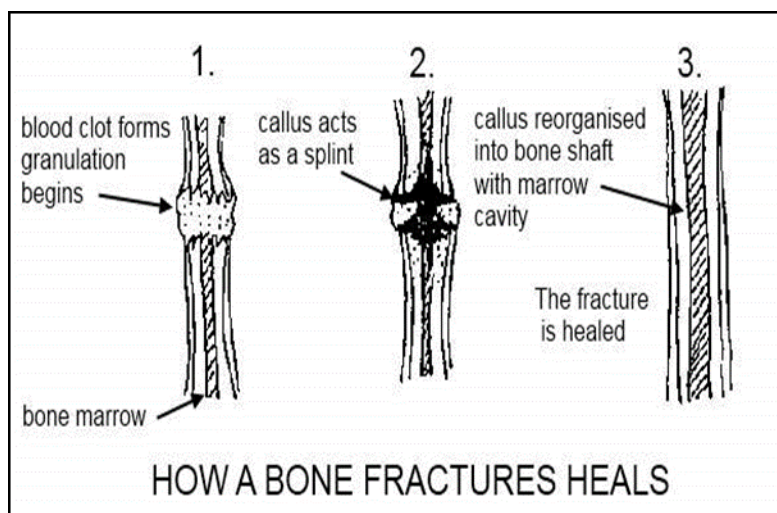
Between the shaft and extremity is a disc of cartilage which is called the epiphysial cartilage. Osteoblasts (bone forming cells) are located in this disc and lay down bone which makes the bone longer. This disc is only active in the human and animal until mature size is reached. After this, the disc ossifies. In humans this happens in the late teens or early twenties.

About one third of the weight of bone consists of fibrous tissues and cells which make a framework. Two thirds consists of the inorganic salts which are deposited within the framework to make bone tissue hard. These salts are chiefly calcium and phosphorus (in fact, calcium phosphate accounts for some 80% of salts deposited in bone). Other salts include calcium carbonate and magnesium phosphate.

FRACTURES AND FRACTURE HEALING

A fracture is simply a break in the bone. If the broken ends of a fractured bone are brought together and immobilised, the normal process of healing will take place. As the fracture occurs, some blood vessels are

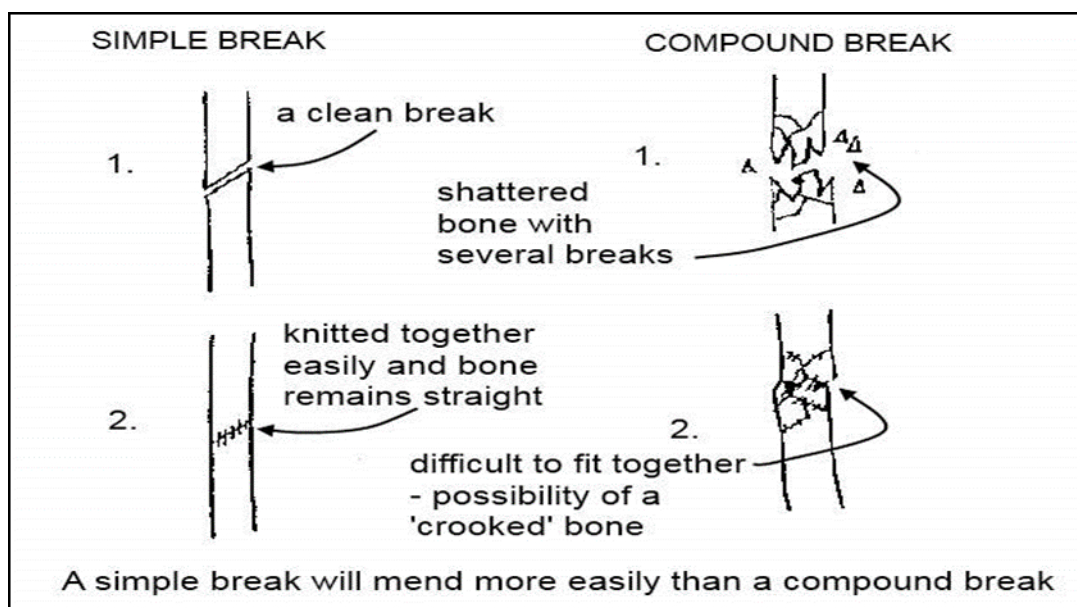
ruptured. This causes blood to pour around the broken ends of the bone. A blood clot forms which is invaded by connective tissue cells. These cells set about forming granulation tissue and new blood capillaries.



At the same time, the osteoblasts from the surface of the bone (the periosteum) divide rapidly and produce a massive amount of osteoid tissue which is called a callus. The callus completely encircles the broken end of the bone and also penetrates some way into the marrow cavity within the shaft.

The callus thus forms an effective splint and prevents movement of the two segments while the fracture heals. As soon as the callus becomes calcified and hard, it has changed into true bone. The callus now reorganises itself to form a typical bone shaft with a marrow cavity. The healing process is now complete.

The process above is straightforward when the break in the bone is clean i.e. there are two level surfaces being knitted together. If the break is a compound one i.e. there are several breaks, or if the bone has been shattered by crushing, healing is much more difficult and there is a risk that the healed bone will not be straight.



TYPES OF BONE

- 1. Long Bones** - These are greater in one dimension than another (e.g. the thigh bone). They serve as a lever and aid support and movement of the body.
- 2. Short Bones** - These are approximately equal in size in height, length and breadth. They have no marrow cavity. They are found in complex joints such as the wrist. They are used to absorb shock.
- 3. Sesamoid Bones** - These bones are so-named because they are shaped like sesame seeds! They are found along the course of tendons where they help to reduce friction or change the course taken by the tendon. A good example of a sesamoid bone is the patella (the knee cap).

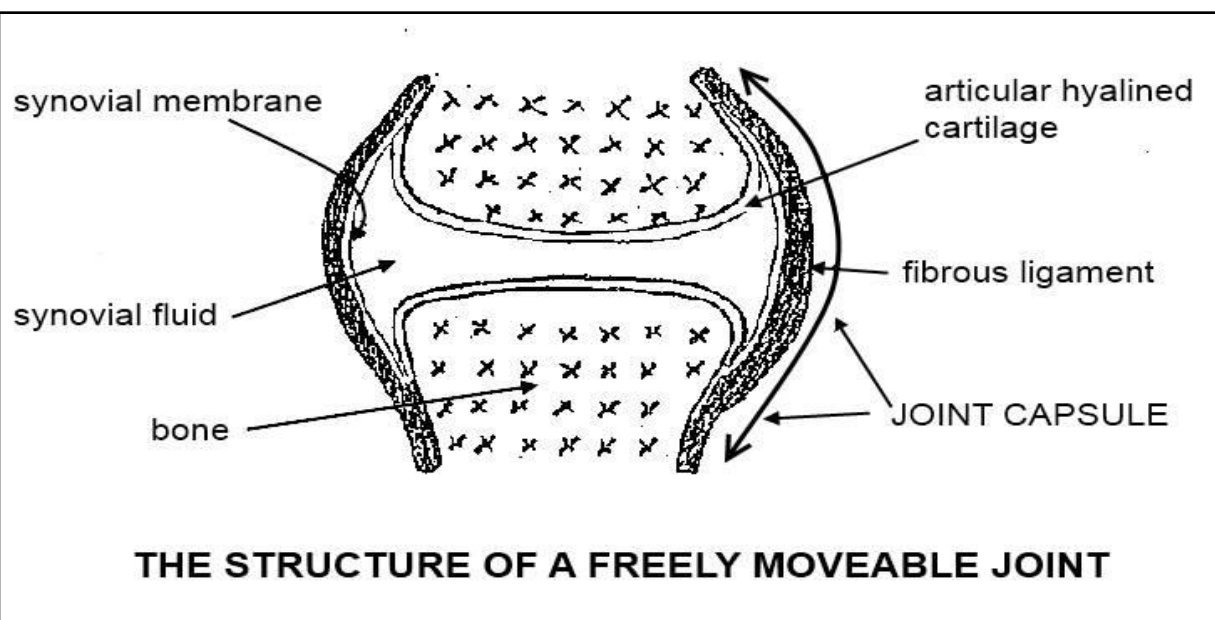
4. **Pneumatic Bones** - These bones contain air spaces and are found in the skull e.g. the nasal bones.
5. **Irregular Bones** - These are unpaired bones. Their functions include protection, support and muscle attachment. The vertebrae are included with these bones.

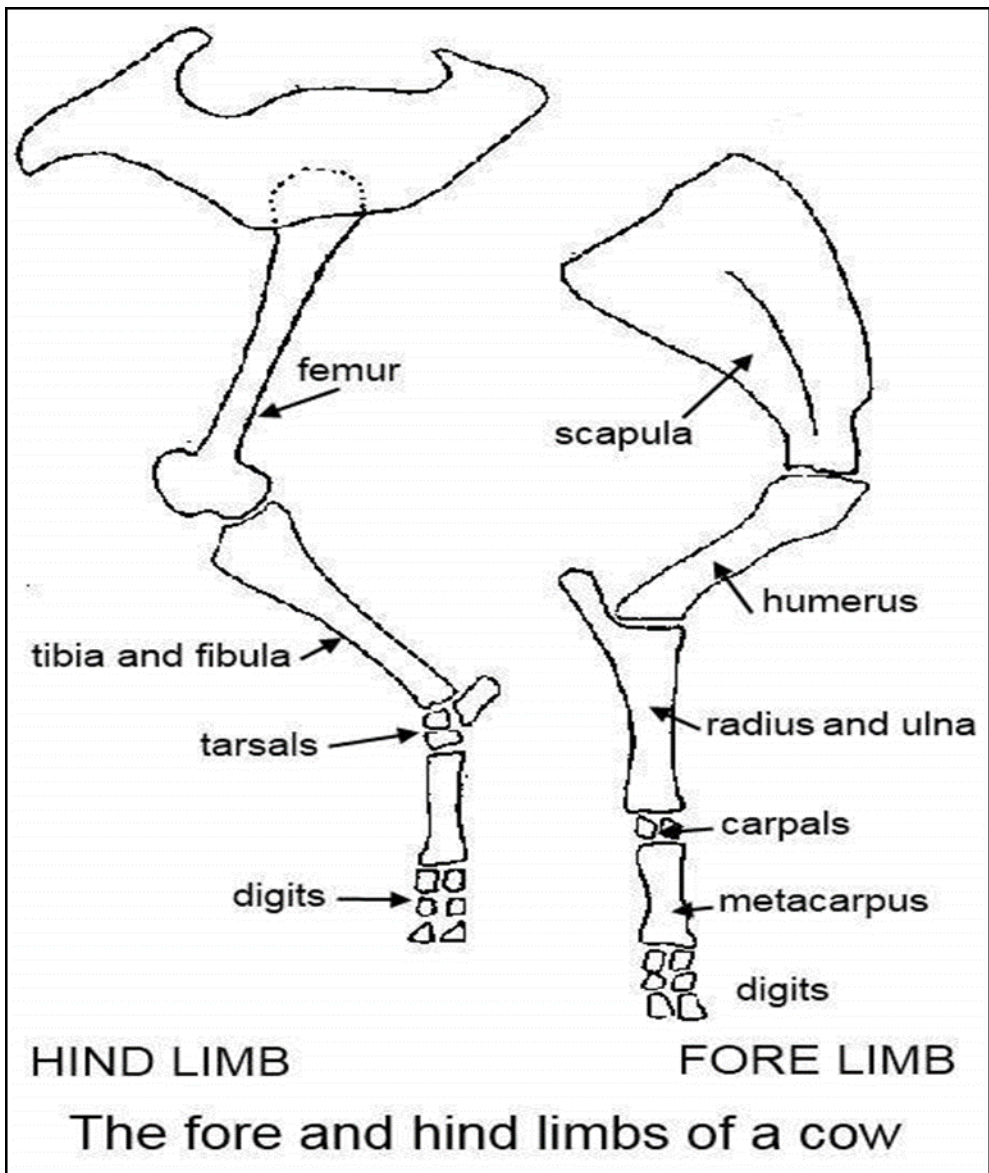
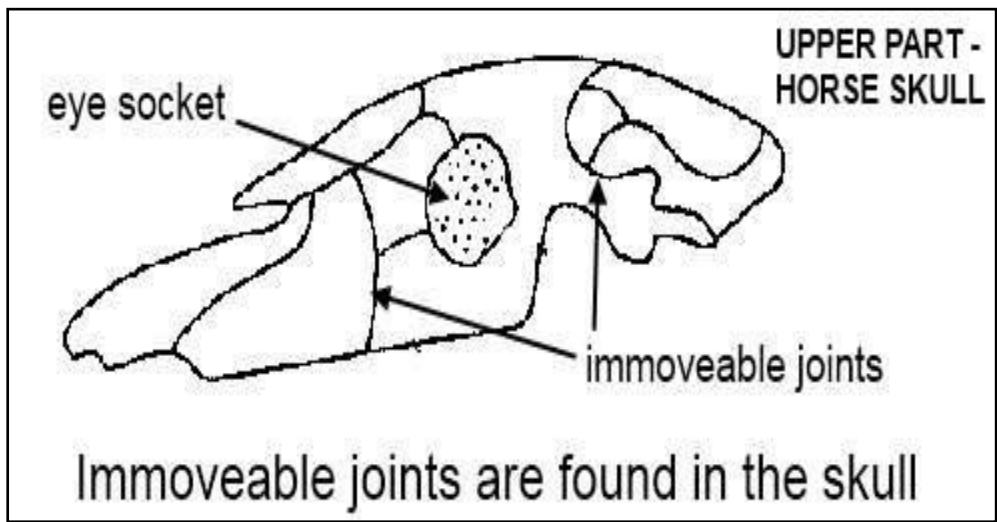
BONE JOINTS

Bones are joined to one another by joints. There are several types of joints:

- **Immoveable** - Examples of immoveable joints are found in the skull. The skull bones cannot move at all.
- **Slightly moveable** - This sort of joint is found in the vertebrae in the back.
- **Freely moveable** - The knee joint or the wrist joint are examples of freely moveable joints. It is important to remember that the joint does not have to be able to move in all directions to be termed "freely moveable". It might move in all directions (like the shoulder joint) or it might move in one plane only (like the knee joint).

The joint is encased by the joint capsule which consists of an outer fibrous ligament which is thick and strong and an inner synovial membrane which is thin and delicate. This membrane secretes synovial fluid or joint oil to lubricate the joint. The surface of the bones involved in movement, are covered by the very smooth articular cartilage which also assists movement.



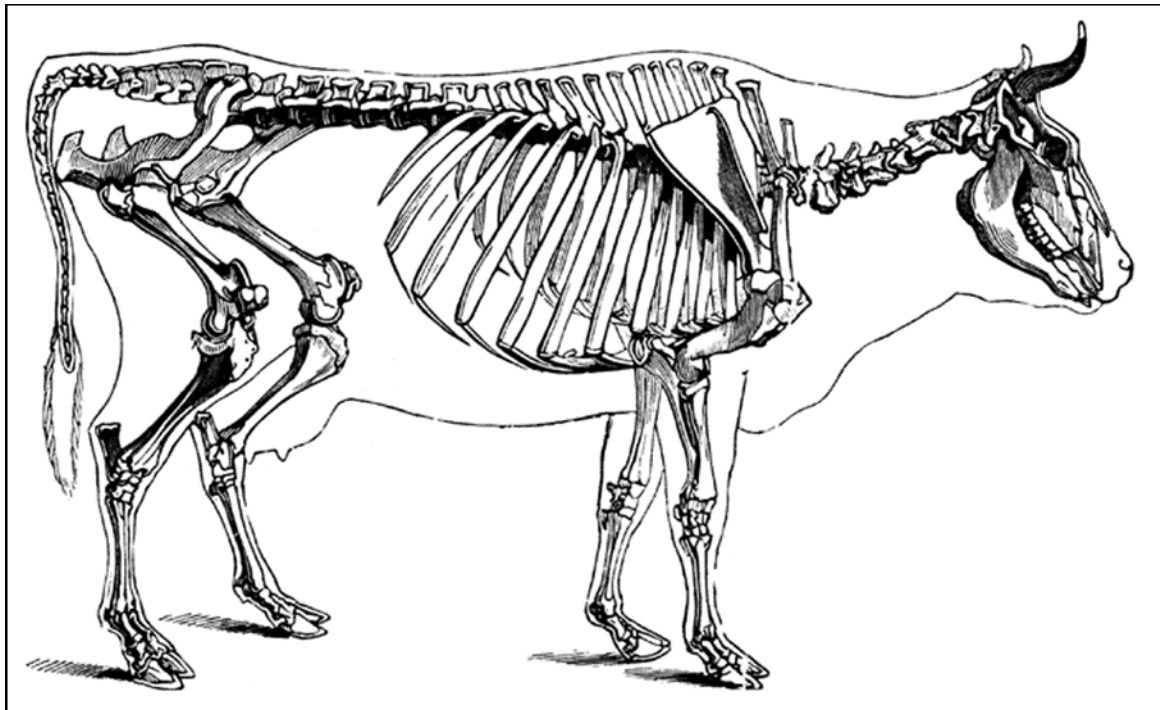
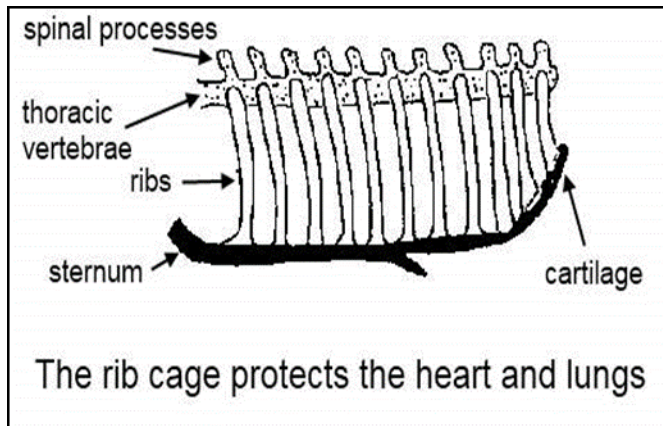


THE SKELETON

The joints connect bones together into a framework called the skeleton. The skeleton carries out several important functions, the most important of which are:

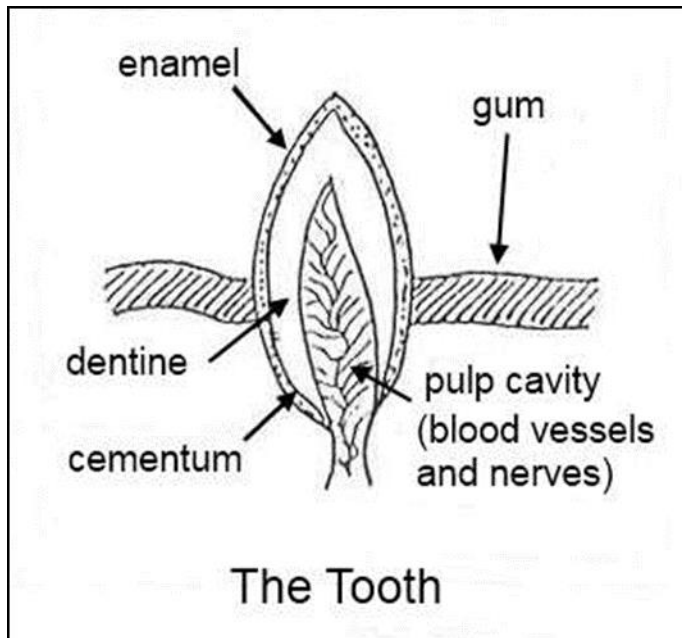
- It provides protection to the vital organs of the body.
- For example, the brain is protected by the skull and the remainder of the central nervous system (the spinal cord) is protected by the vertebral column or backbone. The rib cage protects the heart and lungs (see picture left), while the pelvic girdle covers the uro-genital system.

- The skeleton provides the base for general structure and outline for the mammal (see picture below). It is the frame to which muscles and skin are attached.
- It gives the body rigidity.
- Some of the bones of the skeleton are arranged to act as levers so that movements like walking, running and lifting can be performed.
- The skeleton is a storage site for minerals, particularly calcium, phosphorus and magnesium. These are stored within the bones, and can be used if they are deficient in the animal's diet.
- The bones of the skeleton contain marrow and this plays a part in the formation of blood cells (mainly red blood cells but also part of the white blood cells). This is a very important function of bones.



DENTITION

Dentition is the study of teeth.



Teeth play an important part in the biting, tearing and grinding of food. In addition, farmers can look at the number and condition of teeth in order to tell the age of an animal. This is important when a farmer wants to buy new stock as he needs to know whether the animal he is being sold really is the age it is advertised to be.

In addition, an animal with poor teeth will not be able to eat well enough to keep condition on itself and will prove more of a nuisance than an asset.

Normally, only one third of the tooth is visible above the gum. Soon after the birth of an animal, temporary or milk teeth grow in the mouth. These are replaced by the permanent teeth as the animal grows. In humans, the permanent teeth are replaced from the age of about eight years old. By the time the child is 13-14, most of the permanent teeth should have erupted.

In animals, the age at which milk teeth are replaced is important because this is used to judge the age of the animal, particularly with cattle, sheep and horses.

THE DENTAL FORMULA

The lay-out of the teeth in an animal's jaws is the same for all members of any given species of animal. For example, all cattle of the same age will have the same pattern of teeth. This lay-out is called a dental formula.

We will be looking at the dental formulas of cattle, sheep and pigs in this section. It would be a good idea, when you are working with these animals, to have a look at their teeth yourself. It requires a fair bit of practice to be able to confidently tell the age of an animal using the teeth. In addition, if you have looked into several mouths with teeth in good condition, you will be better equipped to recognise teeth that are in poor condition.

To refresh your memory, there are three types of teeth:

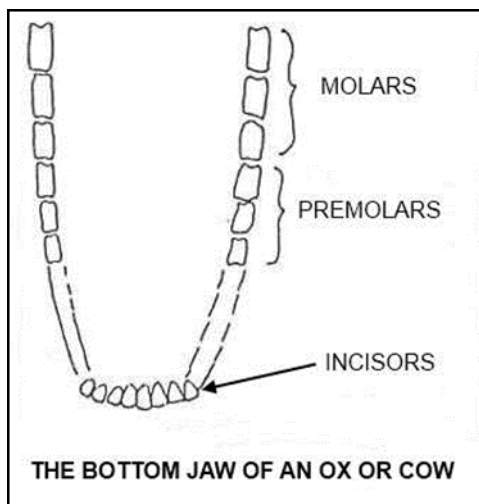
- Incisors - the sharp cutting teeth at the front of the mouth
- Canines - the conical, pointed teeth used for ripping
- Molars & Premolars - the blunt, irregularly shaped teeth used for grinding food into small pieces.

CATTLE

Cattle have molars and premolars in both the top and bottom jaws. They have no canines and they have incisor teeth in the bottom jaw only.

There are no incisor teeth in the top jaws of any cattle - instead, they have what is known as a dental pad which is a toughened area of gum.

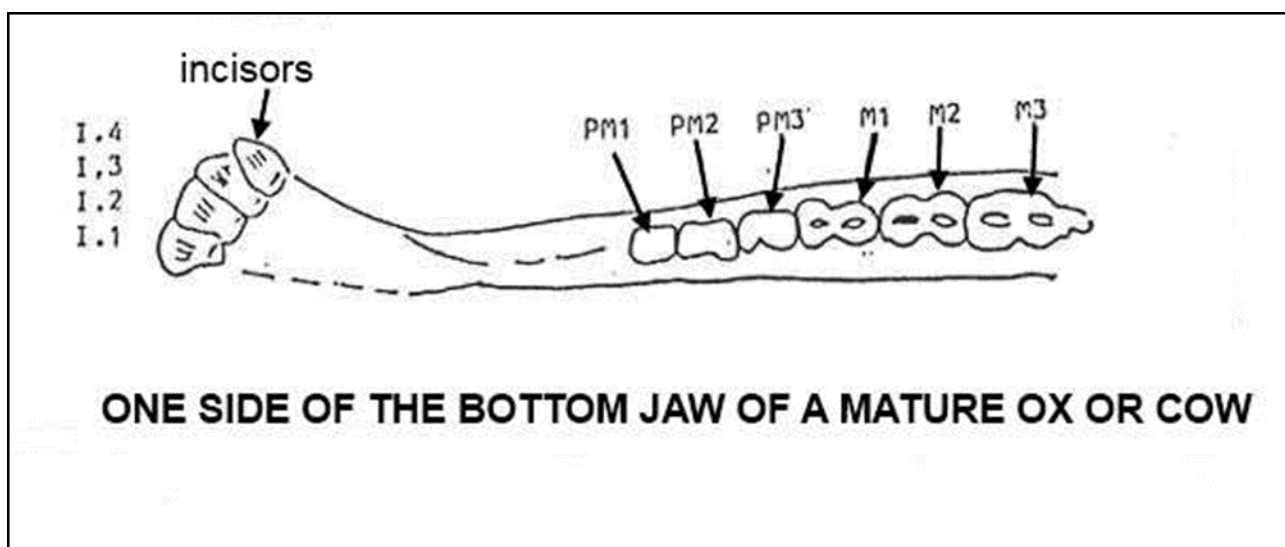
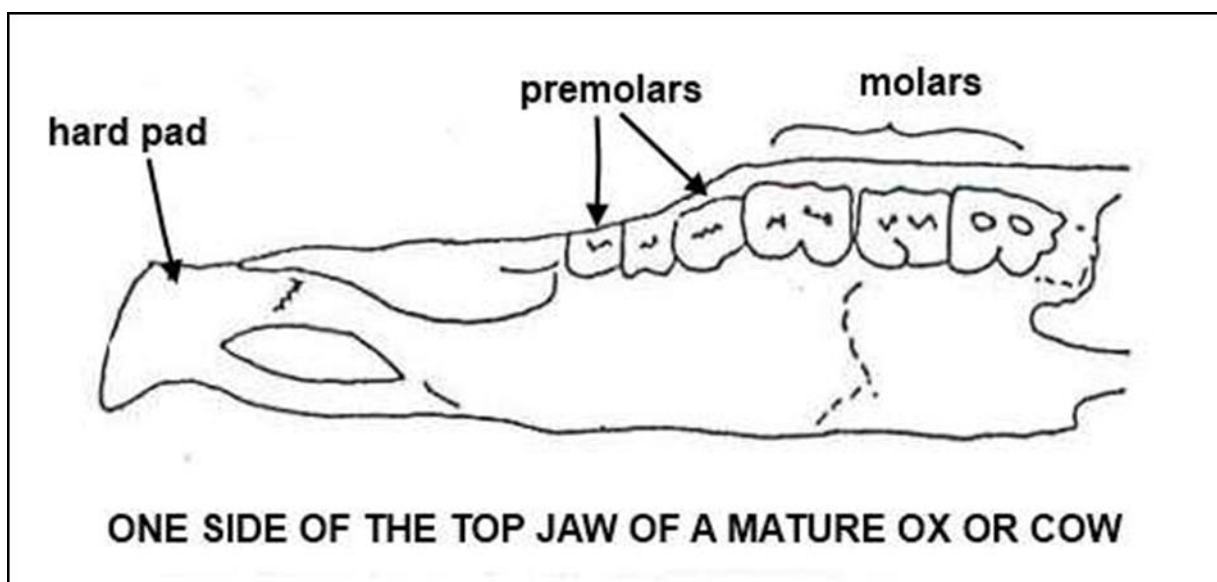
Cattle do not bite grass in the way that horses do, they wrap their tongues around the grass and tear it off, using the papillae on the tongue to increase their grip.



The Dental Formula of an Ox or Cow

Teeth are numbered from the front of the jaw moving backwards towards the throat. They occur in the following order: incisors, canines, premolars, and molars.

Dental formulas are based on this order AND REFER TO ONE SIDE OF THE MOUTH ONLY. (This last point is very important!)



A mature ox or cow has the following teeth:

Top jaw :	Incisors	0
	Canines	0
	Premolars	3
	Molars	3

Bottom jaw :	Incisors	4
	Canines	0
	Premolars	3
	Molars	3

The Dental Formula for cattle is written like this:

0033 = 32 teeth total

4033

This formula refers to the top line referring to one side of the top jaw only and the bottom line referring to one side of the bottom jaw only.

Eruption of permanent teeth

As mentioned earlier, the age at which the permanent teeth erupt or appear through the gums can be used to judge the age of the animal.

The figures given below are approximate because the times of eruption do vary depending on the breed of the animal and the type of feed it has been having.

Better nutrition causes faster growth and earlier eruption of the permanent teeth than poor feeding.

Approximate ages of cattle when permanent teeth erupt:

Time of Eruption	Incisors	Premolars/Molars
Birth to 1 month	All 8 temporaries	All 12 temporaries
6 months		1st pair permanent molars
15-18 months		2nd pair permanent molars
21-24 months	1st pair (central) permanent	
2 years		3rd pair permanent molars
2 years 6 months	2nd pair permanents	1st & 2nd pairs permanent premolars
3 years	3rd pair permanents	3rd pair permanent premolars
3.5-4 years	4th pair (corner) permanents	

At four years old, it would have all its permanent teeth and would be classed as a "Full Mouth".

SHEEP

Sheep have the same number of permanent teeth as cattle and their Dental Formula is the same:

0033 = 32 teeth total

You can see that they have no incisors in the top jaw but they do have a dental pad in the same way as cattle. Sheep also graze in the same way as cattle - tearing rather than biting at the grass. Once a sheep has become a "full mouth", its teeth seem to wear down quite quickly and they also begin to fall out. The animal has difficulty in feeding and becomes thin and unthrifty. Once ewes lose their teeth they have to be culled. This usually happens about two years after they have become "Full Mouths."

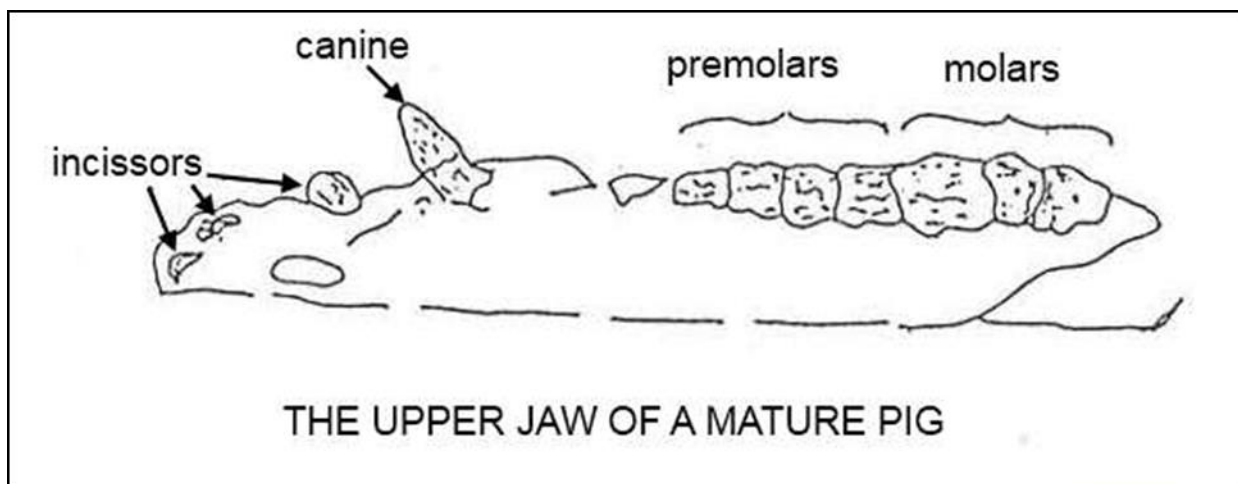
The ages at which the permanent teeth erupt in sheep are given in the following table:

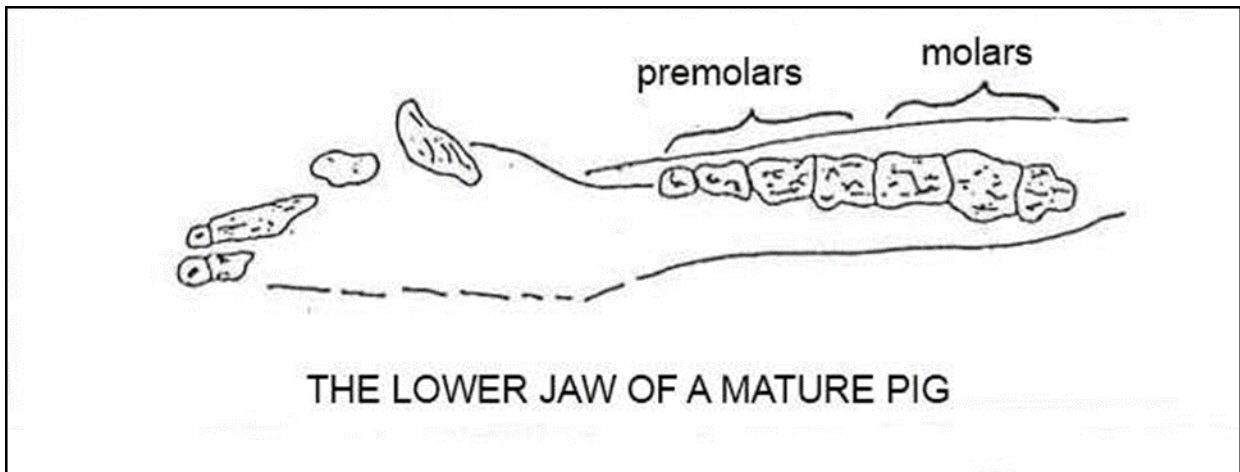
Time of Eruption	Incisors	Premolars/Molars
Birth to 1 month	All 8 temporaries	All 12 temporaries
3 months		1st pair permanent molars
9-12 months		2nd pair permanent molars
12-18 months	1st pair (central) permanents	
18-24 months	2nd pair permanents	3rd pair permanent molars All permanent premolars
2.5-3 years	3rd pair permanents	
3.5-4 years	4th pair (corner) permanents	

At three years, the sheep has all its permanent molars, premolars and incisors and is termed a "Full Mouth."

PIGS

Teeth are not so important in pigs because most baconers and porkers are slaughtered before they reach maturity. It is interesting, however, to look at pigs' dentition more closely as their Dental Formula differs from cattle and sheep.





Pigs have incisors in the bottom and top jaws and they also have well developed canines. In boars, the canines grow to form the tusks and are used as a weapon in fighting.

The Dental Formula for a mature pig is:

$$3143 = 44 \text{ teeth in total}$$

$$3143$$

DENTITION IN DOMESTIC ANIMALS

Cats

Cats are naturally carnivorous. Cat teeth do not have a grinding surface due to their carnivorous nature.

Dental Formula for Cats

Temporary Teeth 3 1 3 = 13 teeth in total

$$3 \ 1 \ 2$$

Permanent Teeth 3 1 3 1 = 15 teeth in total

$$3 \ 1 \ 2 \ 1$$

Dogs

Dogs are also carnivores by nature. However, most pet dogs are fed an omnivorous diet. Dogs do have a grinding surface on some of their mature molars.

Dental Formula for Dogs

Temporary Teeth 3 1 3 = 14

$$3 \ 1 \ 3$$

Permanent Teeth 3 1 4 2 = 21

$$3 \ 1 \ 4 \ 3$$

Rabbits

Rabbits are herbivorous, i.e. feeding on plant material. They are part of the Lagomorph family with hares and have a unique dental arrangement. Their teeth are without roots and continually grow throughout their lives.

Dental Formula for Rabbits

$$\underline{2 \ 0 \ 3 \ 3} = 14$$

$$1 \ 0 \ 2 \ 3$$

Rodents

Rodents belong to the Order Rodentia and include common pets such as mice and rats as wild species of porcupine and capybaras. Rodents can be herbivorous or omnivorous. They are generally gnawing animals possessing large incisors. As with the lagomorphs, they are rootless and continually grow.

Dental Formula for Rats and Mice

$$\frac{1003}{1003} = 8$$

$$1003$$

SET TASK

- Obtain samples of five different types of bones from a butcher. If you cannot get access to the actual bones use the internet to research bones types.
- Study, sketch, and label the sample of different bones - each of these in a way which will distinguish between the samples of those 5 different types of bones.